

# Age-related metabolic changes in the corpus callosum: assessment with MR spectroscopy

Zülkif Bozgeyik, Gülen Burakgazi, Yaşar Şen, Erkin Oğur

## PURPOSE

The aim of this study was to examine metabolite changes in different parts of the corpus callosum (CC), and to relate these changes to different age groups using magnetic resonance spectroscopy (MRS).

## MATERIALS AND METHODS

A total of 76 healthy subjects participated in the study with MRS analyses (39 females and 37 males). Subjects were grouped by age into four groups, in increasing order: Groups 1, 2, 3, and 4. Single-section 2D multivoxel spectroscopy was performed using chemical-shift imaging techniques. The voxels were placed on the rostrum, genu, corpus, and splenium of the CC. Peak metabolite ratios of N-acetylaspartate (NAA)/choline (Cho), NAA/creatine (Cr), and Cho/Cr were calculated from the rostrum, genu, body, and splenium. One way analysis of variance test was performed for the detection of changes in different age groups. Pearson correlation test was performed for correlation of metabolite ratio related to age.

## RESULTS

Statistically significant differences were found for NAA/Cho ratios for the rostrum, corpus, and splenium, and NAA/Cr ratios for the corpus and splenium between Groups 1 and 2, Groups 1 and 3, and Groups 1 and 4. Metabolite ratios of the corpus and splenium were similar. This similarity was also valid for parts of the rostrum and genu.

## CONCLUSION

Metabolite ratios in the CC are influenced by age. Age-related changes and regional metabolite levels may cause these alterations. Analyses of the CC may be informative for the evaluation of white matter. MRS may help to demonstrate metabolite levels and ratios of the CC.

**Key words:** • magnetic resonance spectroscopy  
• corpus callosum • aging

**T**he corpus callosum (CC) is the major commissural pathway between the brain hemispheres. It plays an integral role in relaying sensory, motor, and cognitive information between homologous regions in the two hemispheres. The CC traditionally has been separated into four segments: the rostrum, the genu, the body, and the splenium (1).

Magnetic resonance spectroscopy (MRS) is an imaging modality for monitoring chemical and metabolic changes in areas of interest within the brain. It can provide information about the levels of metabolites, and may be a noninvasive way to help differentiate normal from pathological tissue (2).

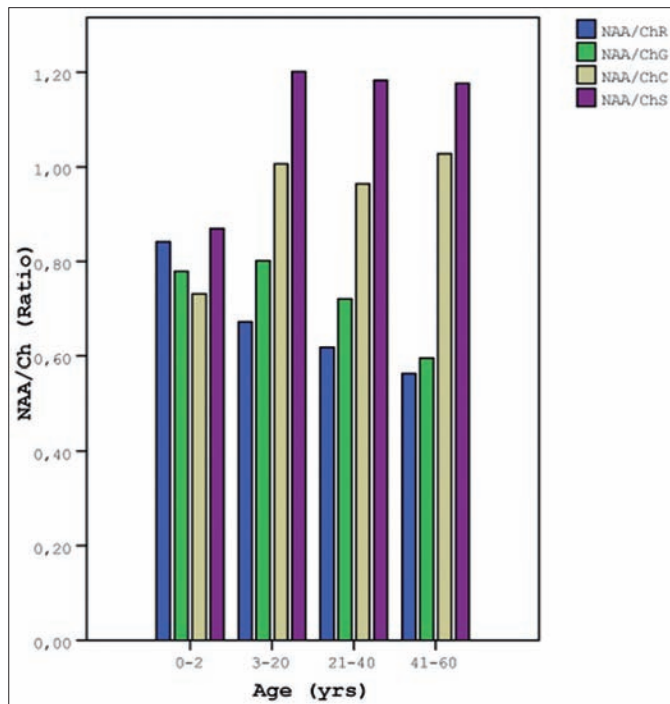
The CC may be affected primarily and secondarily in many pathological entities such as metabolic diseases, infectious disease, and brain tumors. Proper analyses of the CC are important for interpretation of white matter diseases; the CC may be very sensitive to changes in white matter tracts (3). The aim of this study was to determine age-related metabolic changes of different parts of the CC using MRS. To our knowledge, this is first MRS study of metabolite ratios in the CC in healthy subjects.

## Materials and methods

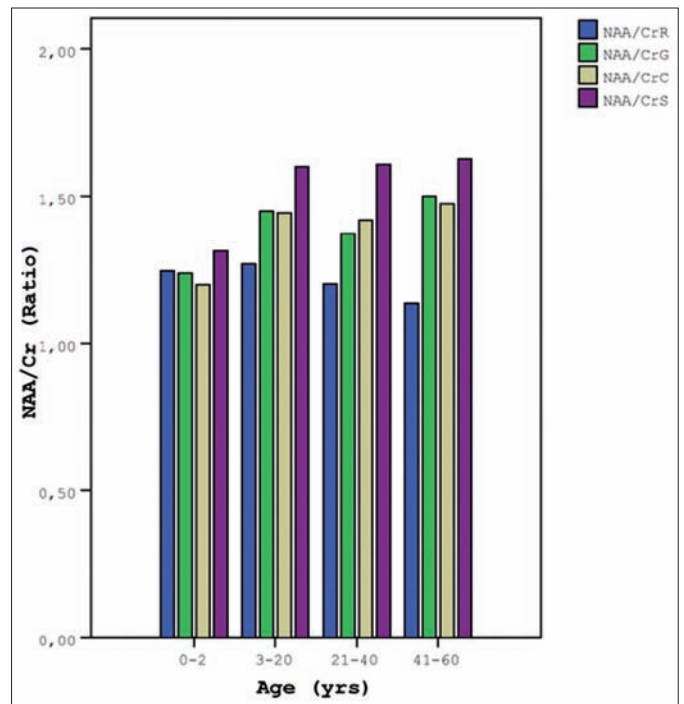
A total of 76 healthy subjects (39 females and 37 males) participated in this study for MRS analyses. The study population was divided by age into four groups. Groups were divided as follows: Group 1, age 0–2 years, mean age  $1.28 \pm 0.34$ ; Group 2, age 3–20 years, mean age  $10.45 \pm 2.35$ ; Group 3, age 21–40 years, mean age  $30.72 \pm 2.74$ ; and Group 4, age 41–60 years, mean age  $49.90 \pm 2.86$ . Group 1 included 10 subjects, and Groups 2, 3, and 4 included 22 subjects, each. The local ethics committee approved this study. Informed consent was obtained from all participants in Groups 3 and 4, and from the parents of all participants in Groups 1 and 2.

Exclusion criteria were intra-axial or extra-axial tumor, seizure disorder, hydrocephalus, history of previous radiotherapy or chemotherapy, metabolic disease, intracranial hemorrhage, white matter disease, size abnormalities of the CC, and abnormal T2 signals of the CC or other brain tissue.

MR imaging was performed using a 1.5-T magnet system (General Electric Signa EXCITE high speed scanner, Milwaukee, Wisconsin, USA) equipped with high-speed gradients. Axial T2-weighted images (TR/TE, 3775/102 ms) and sagittal T2-weighted (TR/TE, 5425/85 ms) and T1-weighted (TR/TE, 525/16 ms) images were obtained from all patients to confirm the absence of any structural and signal abnormality of the brain. Single section 2D multivoxel spectroscopy was performed using chemical shift imaging (CSI) techniques at the level of the selected image. In addition, a chemical shift selective saturation pulse was used to achieve water suppression while the volume of interest was kept inside the brain parenchyma. Using a T1-weighted sagittal MR image, we identified all portions of the CC, and used this information to prescribe the multivol-



**Figure 1.** NAA/Cho ratio in different parts of the corpus callosum, related to age groups (NAA, *N*-acetylaspartate; Cho, choline; R, rostrum; G, genu; C, corpus; S, splenium).



**Figure 2.** NAA/Cr ratio in different parts of the corpus callosum, related to age groups (NAA, *N*-acetylaspartate; Cr, creatine; R, rostrum; G, genu; C, corpus; S, splenium).

ume localized  $^1\text{H}$ -MRS. The acquisition parameters of the MRS were TR/TE, 520/13 ms; NEX, 1; field of view (FOV), 12x12 cm with 16 x 16 phase-encoding steps; acquisition time, 5 minutes.

Three orthogonal baseline images were obtained; 1 cm<sup>3</sup>-volume of interest (VOI) was identified. The voxels were placed on the rostrum, genu, corpus, and splenium of the CC. Choline (Cho), creatine (Cr), *N*-acetylaspartate (NAA) signals were obtained. Resonances were assigned as follows: Cr, 3.02 ppm; Cho, 3.2 ppm; and NAA, 2.02 ppm. Peak metabolite ratios (NAA/Cr, NAA/Cho, and Cho/Cr) were calculated from the rostrum, genu, body, and splenium of the CC. Three measurements were obtained for every part of the CC, e.g. NAA/Cho-rostrum, Cho/Cr-rostrum, and NAA/Cr-rostrum. The analyses of the spectral dataset were performed with the manufacturer-supplied software package program of the MR system (Advantage Windows, software version 2.0, GE Medical Systems).

Statistical analysis was performed with the Statistical Package for the Social Sciences 12.0, a software package program (SPSS Inc., Chicago, Illinois, USA) using personal computer. One way analysis of variance (ANOVA) test was performed for the detection of changes at differ-

ent age groups (Tukey test was used as a post hoc test). Pearson correlation test was performed for correlation of metabolite ratio related to age. A *P* value less than 0.05 was considered to be statistically significant.

### Results

Metabolite ratios of the corpus and splenium were similar. This similarity was also observed in parts of the rostrum and genu.

The NAA/Cho ratio for the rostrum and genu was greater in Group 1 than in the other groups. However, this ratio was low in Group 1 for the corpus and splenium. Cho/Cr ratio for the corpus was high in Group 1 compared with the other groups. The NAA/Cr ratio for the genu, corpus, and splenium was higher in Group 1 than in the other groups (Figs. 1–3).

Statistically significant differences were found for NAA/Cho ratios for rostrum, corpus, and splenium and NAA/Cr ratios for corpus and splenium between Groups 1 and 2, Groups 1 and 3, and Groups 1 and 4. NAA/Cr-rostrum and Ch/Cr-rostrum ratios were not statistically significant between groups. All metabolite ratio values are given in Table.

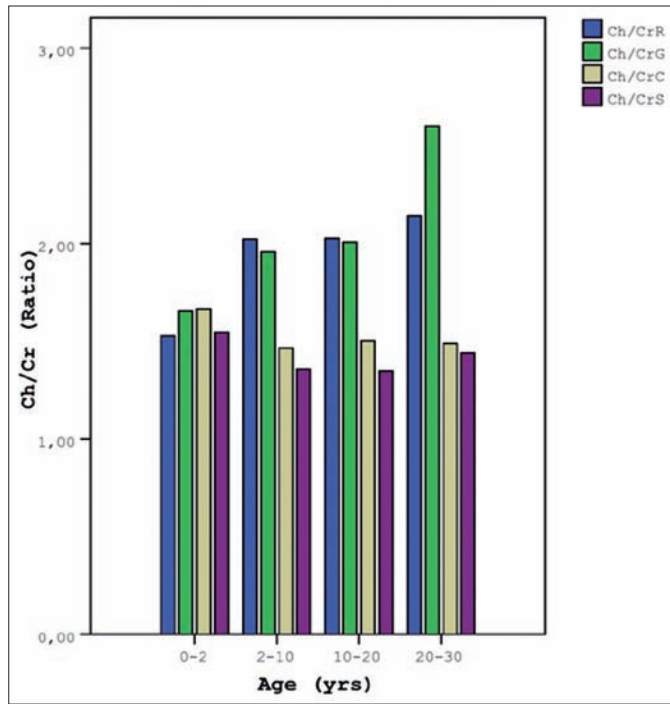
Correlation test was performed for metabolite ratio related to age. Metab-

olite ratios of NAA/Cho of the rostrum and genu decreased with age ( $r$ : -0.431, -0.395;  $P$  < 0.05). Metabolite ratios of NAA/Cr of rostrum decreased with age, but this difference was not statistically significant ( $r$ : -0.136,  $P$  > 0.05). In contrast, ratios of NAA/Cho and NAA/Cr of corpus and splenium increased with age ( $r$ : 0.294, 0.246, 0.328, 0.239;  $P$  < 0.05), and Cho/Cr ratios of the genu increased with age ( $r$ : 0.451,  $P$  < 0.05). The metabolite ratio of Cho/Cr in the rostrum increased with age, but was not statistically significant ( $r$ : 0.164,  $P$  > 0.05); however, this ratio decreased with age for the corpus and splenium ( $r$ : -0.102, -0.028;  $P$  > 0.05), also not statistically significant.

### Discussion

The CC is the largest connective fiber bundle in the brain; it accounts for approximately one-ninth of the supratentorial volume (4). Midline sagittal MR images show the CC as a thick crescent of white matter. Proper analysis of the CC is an easy and extremely important step in the accurate interpretation of the pediatric brain magnetic resonance imaging (MRI).

The corpus and its precursors develop between the 8th and 20th gestational weeks, a time during which the basal



**Figure 3.** Cho/Cr ratio in different parts of the corpus callosum, related to age groups (Cho, choline; Cr, creatine; R, rostrum; G, genu; C, corpus; S, splenium).

ganglia, cerebral, and cerebellar hemispheres are forming. Not surprisingly, the presence of an anomaly of the CC strongly correlates with anomalous development of other portions of the brain (5). The completely formed CC

continues to enlarge throughout infancy, childhood, and young adulthood. There are many studies addressing the question of when the CC reaches adult size. One large study suggests that the CC reaches its adult size by age 10–12

years (6). Other studies have demonstrated growth up to approximately 15 years, 18 years, or 20 years (6–8).

White matter of the brain is composed of separate bundles of axons; callosal axons connect homologous areas in the cortices of the cerebral hemispheres (5). In one study, increased CC size in patients with neurofibromatosis type 1 was shown to be primarily due to an increase in white matter volume (6). Thus, analyses of the CC may reflect white matter, and may be informative with regard to normal and pathologic conditions of the white matter.

MRS is a noninvasive modality to investigate biochemical alterations in neural structures caused by various brain diseases (9). In vivo brain metabolism can be evaluated by means of MRS (10). The prominent resonances detected on MRS in normal brains include those of NAA, Cho and Cr.

NAA is an amino acid located exclusively in neuronal cell bodies, dendrites, and axons (6). It is the most sensitive metabolite for central nervous system, and is accepted as a neuroaxonal marker. Abnormalities of neuronal structures lead to reductions in NAA quantity (9). Cho can be viewed as an indirect marker of myelination and cell membrane metabolism. An increase in the Cho peak is associated with conditions such as brain tumors and demyelinating disease. Decreased concentration of Cho may be due to changes in dynamic behaviour of the membrane lipids and/or decreased membrane turnover (11). In practice, alterations in the NAA/Cho ratio have been reported with findings suggestive of neuronal damage caused by neuronal disorders (12, 13). Since Cr is relatively constant throughout the normal brain tissue and in different pathological conditions, it is often used as a reference resonance for the measurement of relative changes in NAA or Cho or both (11). A decreased ratio of NAA/Cr provides evidence of axonal damage, neuronal destruction, breakdown of neuronal function, or displacement of neurons (3, 14).

In the literature, there are many MRS reports related to levels and ratios of NAA, Cho, and Cr metabolites. These reports describe different aspects of levels and ratios of these metabolites. Katoda et al. performed an MRS study of the region of the semiovale in normal subjects aged 4–88 years. They found a decreased ratio of NAA/Cho between

**Table.** Metabolite ratios of age groups for segments of the corpus callosum

		Age			
		0–2 (Group 1)	3–20 (Group 2)	21–40 (Group 3)	41–60 (Group 4)
NAA/Cho	R	0.84 ± 0.03 <sup>a</sup>	0.67 ± 0.04 <sup>c</sup>	0.61 ± 0.03	0.56 ± 0.03
	G	0.77 ± 0.04 <sup>c</sup>	0.80 ± 0.05 <sup>c</sup>	0.72 ± 0.03 <sup>c</sup>	0.59 ± 0.03
	C	0.73 ± 0.03 <sup>a</sup>	1.00 ± 0.03	0.96 ± 0.03	1.02 ± 0.03
	S	0.86 ± 0.05 <sup>a</sup>	1.02 ± 0.04	1.18 ± 0.05	1.17 ± 0.04
Cho/Cr	R	1.52 ± 0.08	2.02 ± 0.15	2.02 ± 0.20	2.14 ± 0.22
	G	1.65 ± 0.09 <sup>c</sup>	1.95 ± 0.08 <sup>c</sup>	2.00 ± 0.13 <sup>c</sup>	2.60 ± 0.13
	C	1.66 ± 0.05 <sup>a</sup>	1.46 ± 0.04	1.49 ± 0.04	1.48 ± 0.04
	S	1.35 ± 0.10 <sup>b</sup>	1.34 ± 0.04	1.44 ± 0.03	1.40 ± 0.07
NAA/Cr	R	1.26 ± 0.02	1.27 ± 0.05	1.20 ± 0.09	1.13 ± 0.11
	G	1.25 ± 0.02 <sup>c</sup>	1.44 ± 0.05	1.37 ± 0.07	1.50 ± 0.06
	C	1.19 ± 0.03 <sup>a</sup>	1.44 ± 0.03	1.41 ± 0.03	1.47 ± 0.03
	S	1.32 ± 0.05 <sup>a</sup>	1.60 ± 0.03	1.60 ± 0.02	1.62 ± 0.07

Cho, choline; Cr, creatine; NAA, N-acetylaspartate; R, rostrum; G, genu; C, corpus; S, splenium.

<sup>a</sup> vs Groups 2, 3 and 4,  $P < 0.05$

<sup>b</sup> vs Group 3,  $P < 0.05$

<sup>c</sup> vs Group 4,  $P < 0.05$

the ages of 18.5 and 85 years (12). The NAA/Cho ratio is related to the increase in neuronal content relative to the density of axons, which may correspond to neuronal maturation. Myelination is related to full functional capacity of neuronal interconnections, and is not completed before adolescence (15). Gruber et al. found that the NAA/Cho and NAA/Cr ratios in the semiovale, frontal, and parietal white matter were greater in elderly subjects than in younger adults (16). Brooks et al. found a decrease in NAA level with age, and no change of Cr and Cho levels with age (17). Harada et al. performed multivariate analysis of regional differences and normal age-related changes of metabolites in the lentiform nucleus and frontal lobe. They concluded that normal changes of metabolites with age differed depending on the cerebral region (18). We found a decreased ratio of NAA/Cho in parts of the rostrum and genu, and these results are in agreement with those of the aforementioned studies.

In contrast to these studies, we found increased NAA/Cho ratios in the corpus and splenium of the CC. Angelie et al. found that NAA/Cho and NAA/Cr ratios decreased with age and that the Cho/Cr ratio increased with age in the cortex, semiovale, and temporal lobe (19). In our study, Cho/Cr ratios increased with age in the rostrum and genu of the CC. These findings are similar to the findings of Angelie et al; however, we found decreased Cho/Cr ratios in the corpus and splenium of the CC. Saunders et al. and Pfefferbaum et al. measured metabolite concentrations, and found a significant increase in Cr and/or Cho with age, but constant NAA levels (20, 21). We found an increased NAA/Cr ratio in the corpus and splenium, and a decreased NAA/Cr ratio in the rostrum and genu. The study populations of Saunders et al. and Pfefferbaum et al. were older than our study group. Thus, the observed increase in Cr and Cho levels may be related to the older population.

We found significant changes of metabolite ratios in Group 1 in comparison with the other groups. But, this is not true among Group 2, Group 3, and Group 4. These results may reflect that despite the fact that metabolite alterations may be seen in all ages, these alterations are more prominent in the early years of life than in advanced years.

The topography of the CC is well defined. Fibers from the inferior frontal

lobes and inferior parietal lobes cross in the genu. The fibers in the remaining parts of the frontal and parietal lobes cross in the body of the CC. The temporal and occipital lobe fibers cross in the splenium (22). We believe that different metabolite ratios of the rostrum/genu and corpus/splenium are related to the different metabolite levels in the CC. Also, developmental processes of different anatomic regions of white matter tracts may influence these alterations.

Different metabolite ratios and levels in different parts of the brain have been reported in the literature. Many of them reflect developmental and age-related changes in gray and white matter. Our work shows that metabolite ratios of the CC are influenced by age. We believe that not all metabolite ratio alterations of the CC are pathologic, but that age-related changes and regional metabolite levels may cause these alterations. Analyses of the CC may be informative for evaluation of white matter. MRS may be helpful to demonstrate metabolite levels and ratios of the CC, and may complement MR imaging for evaluation of white matter tracts.

#### References

- Hetts SW, Sherr EH, Chao S, Gobuty S, Barkovich AJ. Anomalies of the corpus callosum: an MR analysis of the phenotypic spectrum of associated malformations. *AJR Am J Roentgenol* 2006; 187:1343-1348.
- Alkan A, Kutlu R, Kocak G, et al. Brain MR spectroscopy in children with a history of rheumatic fever with a special emphasis on neuropsychiatric complications. *Eur J Radiol* 2004; 49:224-228.
- Oh J, Henry RG, Genain C, Nelson SJ, Pelletier D. Mechanisms of normal appearing corpus callosum injury related to pericallosal T1 lesions in multiple sclerosis using directional diffusion tensor and 1H MRS imaging. *J Neurol Neurosurg Psychiatry* 2004; 75:1281-1286.
- Atlas SW, Zimmerman RA, Bilaniuk LT, et al. Corpus callosum and limbic system: neuroanatomic MR evaluation of developmental anomalies. *Radiology* 1986; 160:355-362.
- Barkovich AJ. Analyzing the corpus callosum. *AJNR Am J Neuroradiol* 1996; 17:1643-1645.
- Dubovsky EC, Booth TN, Vezina G, Samango-Sprouse CA, Palmer KM, Brasseux CO. MR imaging of the corpus callosum in pediatric patients with neurofibromatosis type 1. *AJNR Am J Neuroradiol* 2001; 22:190-195.
- Schaefer GB, Thompson JN Jr, Bodensteiner JB, Hamza M, Tucker RR, Marks W, et al. Quantitative morphometric analysis of brain growth using magnetic resonance imaging. *J Child Neurol* 1990; 5:127-130.

- Pujol J, Vendrell P, Junqué C, Martí-Vilalta JL, Capdevila A. When does human brain development end? Evidence of corpus callosum growth up to adulthood. *Ann Neurol* 1993; 34:71-75.
- Cecil KM, Jones BV. Magnetic resonance spectroscopy of the pediatric brain. *Top Magn Reson Imaging* 2001; 12:435-452.
- Alkan A, Sarac K, Kutlu R, et al. Early- and late-state subacute sclerosing panencephalitis: chemical shift imaging and single-voxel MR spectroscopy. *AJNR Am J Neuroradiol* 2003; 24:501-506.
- Sarac K, Akinci A, Alkan A, Aslan M, Baysal T, Ozcan C. Brain metabolite changes on proton magnetic resonance spectroscopy in children with poorly controlled type 1 diabetes mellitus. *Neuroradiology* 2005; 47:562-565.
- Kadota T, Horinouchi T, Kuroda C. Development and aging of the cerebrum: assessment with proton MR spectroscopy. *AJNR Am J Neuroradiol* 2001; 22:128-135.
- Tzika AA, Vajapeyam S, Barnes PD. Multivoxel proton MR spectroscopy and hemodynamic MR imaging of childhood brain tumors: preliminary observations. *AJNR Am J Neuroradiol* 1997; 18:203-218.
- Eichler FS, Itoh R, Barker PB, et al. Proton MR spectroscopic and diffusion tensor brain MR imaging in X-linked adrenoleukodystrophy: initial experience. *Radiology* 2002; 225:245-252.
- Yakovlev PI, Lecours AR. The myelogenic cycles of regional maturation of the brain. In: Minkowski A, ed. *Regional development of the brain in early life*. Oxford: Blackwell, 1967; 3-70.
- Gruber S, Pinker K, Riederer F, et al. Metabolic changes in the normal aging brain: consistent findings from short and long echo time proton spectroscopy. *Eur J Radiol* 2008; 68:320-327.
- Brooks JC, Roberts N, Kemp GJ, Gosney MA, Lye M, Whitehouse GH. A proton magnetic resonance spectroscopy study of age-related changes in frontal lobe metabolite concentrations. *Cereb Cortex* 2001; 11:598-605.
- Harada M, Miyoshi H, Otsuka H, Nishitani H, Uno M. Multivariate analysis of regional metabolic differences in normal ageing on localised quantitative proton MR spectroscopy. *Neuroradiology* 2001; 43:448-452.
- Angelie E, Bonmartin A, Boudraa A, Gonnard PM, Mallet JJ, Sappey-Marinié D. Regional differences and metabolic changes in normal aging of the human brain: proton MR spectroscopic imaging study. *AJNR Am J Neuroradiol* 2001; 22:119-127.
- Saunders DE, Howe FA, van den Boogaart A, Griffiths JR, Brown MM. Aging of the adult human brain: in vivo quantitation of metabolite content with proton magnetic resonance spectroscopy. *J Magn Reson Imaging* 1999; 9:711-716.
- Pfefferbaum A, Adalsteinsson E, Spielman D, Sullivan EV, Lim KO. In vivo spectroscopic quantification of the N-acetyl moiety, creatine, and choline from large volumes of brain gray and white matter: effects of normal aging. *Magn Reson Med* 1999; 41:276-284.
- Carpenter MB. *Core text of neuroanatomy*. 2nd ed. Baltimore: Williams & Wilkins, 1990; 37.